



## The management of gastric polyps

Andrew F Goddard, Rawya Badreldin, D Mark Pritchard, et al.

*Gut* 2010 59: 1270-1276 originally published online July 30, 2010  
doi: 10.1136/gut.2009.182089

---

Updated information and services can be found at:  
<http://gut.bmj.com/content/59/9/1270.full.html>

---

*These include:*

### References

This article cites 71 articles, 14 of which can be accessed free at:  
<http://gut.bmj.com/content/59/9/1270.full.html#ref-list-1>

### Email alerting service

Receive free email alerts when new articles cite this article. Sign up in the box at the top right corner of the online article.

---

### Notes

---

To request permissions go to:  
<http://group.bmj.com/group/rights-licensing/permissions>

To order reprints go to:  
<http://journals.bmj.com/cgi/reprintform>

To subscribe to BMJ go to:  
<http://journals.bmj.com/cgi/ep>

# The management of gastric polyps

Andrew F Goddard,<sup>1</sup> Rawya Badreldin,<sup>2</sup> D Mark Pritchard,<sup>3</sup> Marjorie M Walker,<sup>4</sup> Bryan Warren,<sup>5</sup> on behalf of the British Society of Gastroenterology

<sup>1</sup>Digestive Diseases Centre, Royal Derby Hospital, Derby, UK  
<sup>2</sup>Department of Gastroenterology, James Paget Hospital, Great Yarmouth, Norfolk, UK

<sup>3</sup>Division of Gastroenterology, School of Clinical Sciences, University of Liverpool, UK

<sup>4</sup>Department of Histopathology, Faculty of Medicine, Imperial College, London, UK

<sup>5</sup>Department of Pathology, John Radcliffe Hospital, Oxford, UK

## Correspondence to

Dr Andrew F Goddard, Digestive Diseases Centre, Royal Derby Hospital, Uttoxeter Road, Derby DE22 3NE, UK; [andrew.goddard@derbyhospitals.nhs.uk](mailto:andrew.goddard@derbyhospitals.nhs.uk)

Revised 19 February 2010

Accepted 24 February 2010

## ABSTRACT

**Background** Gastric polyps are important as some have malignant potential. If such polyps are left untreated, gastric cancer may result. The malignant potential depends on the histological type of the polyp. The literature base is relatively weak and any recommendations made must be viewed in light of this.

**Definition** Gastric polyps are sessile or pedunculated lesions that originate in the gastric epithelium or submucosa and protrude into the stomach lumen.

**Malignant potential** Depending on histological type, some gastric polyps (adenomas and hyperplastic polyps) have malignant potential and are precursors of early gastric cancer. They may also indicate an increased risk of intestinal or extra-intestinal malignancy.

## SUMMARY OF RECOMMENDATIONS (QUALITY OF EVIDENCE, BENEFIT/HARM RATIO, STRENGTH OF RECOMMENDATION)

- ▶ All types of gastric polyp detected at endoscopy need to be sampled for which forceps biopsy usually suffices (*moderate, net benefit, qualified*)
- ▶ Biopsy of intervening non-polypoid gastric mucosa is recommended for all hyperplastic and adenomatous polyps (*moderate, uncertain trade-offs, qualified*)
- ▶ If *Helicobacter pylori* is detected in patients with hyperplastic and adenomatous polyps, it should be eradicated (*moderate, net benefit, qualified*)
- ▶ All gastric polyps with dysplastic foci and symptomatic polyps should be completely removed (*moderate, net benefit, qualified*)
- ▶ All gastric adenomatous polyps should be removed when safe to do so (*high, net benefit, definitive*)
- ▶ If adenomatous polyps are detected, an examination of the whole stomach should be made for mucosal abnormalities and any such abnormalities should be biopsied (*moderate, net benefit, definitive*)
- ▶ Familial adenomatous polyposis should be considered as a diagnosis in young patients with numerous fundic gland polyps (*low, uncertain trade offs, qualified*)
- ▶ Endoscopists performing polypectomies must be proficient in performing endoscopic haemostasis techniques (*low, net benefits, definitive*)
- ▶ Repeat gastroscopy should be performed at 1 year for all polyps with dysplasia that have not been removed (*moderate, net benefits, qualified*)
- ▶ Repeat gastroscopy should be performed at 1 year following complete polypectomy for high risk polyps (*moderate, net benefits, qualified*)

## ORIGIN AND PURPOSE OF THESE GUIDELINES

The widespread use of endoscopy has resulted in increased detection of gastric mucosal lesions, many of which are found incidentally. Gastric polyps do not represent a uniform entity and encompass a wide variety of pathology that has differing malignant potential and there are currently no guidelines for the management of these lesions.

This guideline aims to characterise gastric polyps and provide a framework for management. However, recommendations for diagnosis and treatment of these polyps remain controversial, as there is no consensus. Specifically, these guidelines do not cover the management of early gastric cancer.

## Scope

These guidelines are primarily intended for all endoscopists performing gastroscopy.

## Literature search

A search of Medline was made using key words: gastric polyps, adenomas, hyperplastic polyps, fundic gland polyps, inflammatory fibroid polyps, familial adenomatous polyposis, juvenile polyps, juvenile polyposis, Peutz–Jeghers' syndrome and Cowden's disease.

## Grading of recommendations

The quality of evidence for recommendations made in these guidelines based on the 'GRADE' system.<sup>1</sup> Each recommendation is graded according to the quality of evidence, the relative benefit/harm of following the recommendation and the strength of recommendation.

Quality of evidence is graded as: **high**—further research very unlikely to change our confidence in the estimate of effect; **moderate**—further research likely to have an important effect on our confidence on the estimate effect and may change the estimate; **low**—further research very likely to have an important impact on our confidence of the estimate of effect and is likely to change the estimate; or **very low**—estimate of effect is very uncertain.

Benefit–harm is graded as: **net benefit**—the intervention clearly does more good than harm; **trade offs**—there are important trade offs between the benefits and harm; **uncertain trade offs**—it is not clear whether the intervention does more good than harm; or **no net benefits**—the intervention clearly does not do more good than harm.

Strength of recommendation is recommended as: **definitive**—a judgement that most informed people would make; or **qualified**—a judgement that the majority of well informed clinicians would make but a substantial minority would not.

### Methodology of guideline preparation

The literature review was performed by the five authors of the guideline and draft guidelines were prepared. The draft guideline was then reviewed by all members of the British Society of Gastroenterology (BSG) Gastroduodenal Section and Pathology Section Committees. Two meetings were held involving all members of the Gastroduodenal Section Committee to redraft the guideline. This redraft, once approved by the committee, was then reviewed by the BSG Clinical Services and Standards Committee. Further changes were made following recommendations from this committee and a consensus guideline prepared.

The consensus guideline was sent to all 279 members of the BSG gastroduodenal section. Members were asked to assess each recommendation made and rate them as 'agree', 'neutral' or 'disagree'. This feedback was collated and a consensus meeting held of ten representatives from the BSG gastroduodenal and pathology sections. The members of this consensus panel are listed in appendix 1. A final version of the guideline was then prepared.

### INTRODUCTION

Polyps are usually asymptomatic and >90% are found incidentally. Larger polyps can present with bleeding, anaemia, abdominal pain or gastric outlet obstruction. Although some types of polyps may have typical appearances at endoscopy the presence of dysplasia cannot be determined without histological assessment. Therefore all types of gastric polyp must be sampled to determine the pre-malignant risk. Some polyps are an expression of a genetic disease and may also indicate an increased risk of intestinal or extra-intestinal malignancy. Other precancerous conditions of the stomach include chronic atrophic gastritis and intestinal metaplasia.

### TYPES AND CLASSIFICATION OF POLYPS

The most common types of benign epithelial gastric polyps (BEGPs) are fundic gland polyps, hyperplastic polyps and adenomas. If there are multiple gastric polyps present, these are usually of the same histological type.<sup>2</sup> The WHO has classified gastric polyps<sup>3-4</sup> but this classification is controversial. An updated classification is suggested in box 1.

#### Fundic gland polyps

Fundic gland polyps (also called Elster's glandular cysts) occur in two distinct clinicopathological settings: as sporadic polyps and polyps associated with the syndrome, familial adenomatous polyposis coli.

#### Sporadic fundic gland polyps

Fundic gland polyps (FGPs) constitute 16–51% of BEGPs<sup>5-7</sup> and may be observed in 0.8–23% of endoscopies.<sup>8-10</sup> They are usually multiple transparent sessile polyps, 1–5 mm in diameter, located in the body and fundus. Microscopy shows cystically dilated glands lined by gastric body type mucosa.<sup>8</sup> A single study<sup>8</sup> of 56 consecutive patients with FGPs suggested they can be diagnosed with a high degree of accuracy based on endoscopic appearance alone.

Sporadic FGPs are usually caused by activating mutations of the beta-catenin gene<sup>11-12</sup> and usually number less than ten.<sup>13</sup> Dysplasia occurs in <1% of sporadic FGPs.<sup>14-16</sup> FGPs are not associated with atrophic gastritis and the prevalence of *Helicobacter pylori* infection is very low in these patients.<sup>17-20</sup> Case reports have shown that *H pylori* infection may have an inhibitory effect on the development of FGPs but the cause of fundic

### Box 1 Classification of gastric polyps

#### Epithelial polyps

- ▶ Fundic gland polyp
- ▶ Hyperplastic polyp
- ▶ Adenomatous polyp
- ▶ Hamartomatous polyps
  - Juvenile polyp
  - Peutz–Jeghers' syndrome
  - Cowden's syndrome
- ▶ Polyposis syndromes (non-hamartomatous)
  - Juvenile polyposis
  - Familial adenomatous polyposis

#### Non-mucosal intramural polyps

- ▶ Gastrointestinal stromal tumour
- ▶ Leiomyoma
- ▶ Inflammatory fibroid polyp
- ▶ Fibroma and fibromyoma
- ▶ Lipoma
- ▶ Ectopic pancreas
- ▶ Neurogenic and vascular tumours
- ▶ Neuroendocrine tumours (carcinoids)

gland polyps remains uncertain, and these polyps may regress or even disappear in time.<sup>21</sup>

#### Proton pump inhibitor-associated gastric polyps

Since 1993 there have been reports of the role of long-term proton pump inhibitors (PPIs) in the genesis of fundic gland polyps.<sup>10-22</sup> In one study FGPs were present in 23% of patients on PPIs compared with 12% of patients not taking a PPI.<sup>10</sup> The polyps are usually small (<1 cm) and occur in the proximal/mid-gastric body.<sup>23</sup> These reports have been retrospective studies and show that the mean interval for polyp development was 32.5 months and that they regress within 3 months of PPI cessation. However, other studies have not demonstrated a definitive link between long-term PPIs and FGPs.<sup>24-26</sup> Similarly, a prospective long (median of 11 years) follow-up study of 230 patients could not show any de novo FGPs.<sup>27</sup> Histologically, in body mucosa, long-term PPI use induces enterochromaffin cell-like (ECL) hyperplasia and typical 'parietal cell protrusion' and glands are lined by cells with a serrated rather than a smooth border.<sup>23</sup>

#### Fundic gland polyps in familial adenomatous polyposis

FGPs are common in patients with familial adenomatous polyposis (FAP) and arise from mutation of the APC gene.<sup>22</sup> In this context, they are usually multiple and can 'carpet' the body of the stomach. Epithelial dysplasia occurs in 25–41% of FAP associated polyps.<sup>15</sup> The management of FAP is discussed later in this guideline.

There is no evidence as to how to differentiate between sporadic FGP and FAP-associated FGP at endoscopy. The presence of dysplastic foci should arouse suspicion of FAP.<sup>28-29</sup> Two studies have shown the presence of colonic adenomas (7–45%) and adenocarcinomas (0–4.7%) in patients with sporadic FGPs.<sup>30-31</sup> However, this high rate of colonic neoplasia has not been confirmed in other studies.

Therefore, while the presence of numerous FGPs may be a manifestation of FAP, there is no clear evidence about the number of polyps needed to indicate further investigation is

## Guidelines

warranted. When considering lower gastrointestinal investigation, it should be noted that almost all cases of classical FAP can be diagnosed on flexible sigmoidoscopy which is safer than colonoscopy.

*Recommendations for the management of FGPs*

- ▶ Polypectomy is not required for sporadic FGPs (moderate, net benefits, definitive).
- ▶ Although FGPs have reliable endoscopic features, biopsy of probable FGPs is recommended to exclude dysplasia or adenocarcinoma (and possible FAP) and to exclude the need for polypectomy as required for other types of polyp (moderate, net benefit, qualified).
- ▶ In patients with numerous FGP who are under 40 years of age, or where biopsies demonstrate dysplasia, colonic investigation should be performed to exclude FAP (low, uncertain trade offs, qualified).

### Hyperplastic polyps

Hyperplastic polyps (HYPPs) constitute 30–93% of all BEGPs<sup>5–7 17</sup> and are sessile or pedunculated polyps less than 2 cm in diameter. They can occur as single polyps usually in the antrum or as multiple polyps throughout the stomach. Multiple hyperplastic polyps are also found in Menetrier's disease. Histologically, there is a proliferation of surface foveolar cells lining elongated, distorted pits that extend deep into the lamina propria. They may contain pyloric glands, chief cells, and parietal cells. Their histological appearance overlaps with hamartomas and inflammatory conditions.

Polyp formation is strongly associated with chronic gastritis; *Helicobacter*-associated gastritis, pernicious anaemia, reactive or chemical gastritis when adjacent to ulcer erosions and around gastroenterostomy stomas.<sup>52 53</sup> Up to 80% of HYPPs have been found to regress after eradication of *H pylori* before endoscopic removal.<sup>34–36</sup>

HYPPs rarely undergo neoplastic progression directly through neoplastic change in the polyp but are associated with an increased risk of synchronous cancer occurring elsewhere in the gastric mucosa. The prevalence of true dysplasia arising in hyperplastic polyps is debated<sup>37–46</sup> and reported rates have varied from 1.9% to 19% and cases of adenocarcinoma have been reported ranging from 0.6% to 2.1%. HYPPs also denote an increased risk of neoplasia in the surrounding abnormal gastric mucosa and are associated with the occurrence of synchronous cancer elsewhere in the gastric mucosa.<sup>40</sup> Multiple biopsies of the intervening mucosa are therefore needed in patients with HYPPs. The risk of adenocarcinoma in the surrounding mucosa is probably higher than in the polyp itself.

There is controversy regarding whether gastric HYPPs can be simply biopsied or whether they should be entirely removed by polypectomy because of the risk of neoplasia and because forceps biopsy sampling may miss the dysplastic foci within a hyperplastic polyp. Some authors recommend performing polypectomy for all small polyps and periodic biopsy of larger hyperplastic polyps that are too big for polypectomy. Others recommend that, as cancer usually occurs in bigger hyperplastic polyps, only large hyperplastic polyps should be removed, due to the risk of gastric polypectomy. Surveillance of hyperplastic polyps that are not removed (either because of number or size) is probably safer than multiple polypectomies but there is no randomised evidence as to which approach should be taken. A single repeat endoscopy at 1 year is reasonable, but repeated surveillance after 1 year is not recommended due to lack of evidence.

One study<sup>47</sup> has suggested that HYPP may cause gastrointestinal blood loss and should be removed in such patients. This has not been confirmed by other studies.

*Recommendations for the management of hyperplastic polyps*

- ▶ Hyperplastic polyps should be biopsied and an examination of the whole stomach should be made for mucosal abnormalities and any abnormalities biopsied (moderate, trade offs, definite)
- ▶ Test for *H pylori* and eradicate when present (high, net benefit, definitive).

### Adenomatous polyps

Gastric adenomas are true neoplasms and are precursors of gastric cancer. They are histologically classified into tubular, villous and tubulovillous types. They constitute 3–26% of BEGPs, are frequently solitary and can be found anywhere in the stomach but are commonly found in the antrum. They frequently arise on a background of atrophic gastritis<sup>48</sup> and intestinal metaplasia, but there is no proven association with *H pylori* infection. Neoplastic progression is greater with polyps larger than 2 cm in diameter<sup>49</sup> and occurs in 28.5–40% of villous adenomas and 5% of tubular adenomas.<sup>17 41 50–55</sup> There is also a strong association between gastric adenoma and synchronous or metachronous gastric adenocarcinoma.<sup>7 44 45</sup> The risk of association between adenomatous polyps and cancer increases with age.<sup>45</sup>

*Recommendations for management of adenomatous polyps*

- ▶ Complete removal of the adenoma should be performed when safe to do so (high, net benefit, definitive).
- ▶ An examination of the whole stomach should be made for mucosal abnormalities and any abnormalities biopsied (high, net benefit, definitive).
- ▶ Endoscopic follow-up is required following resection of gastric adenomas. Endoscopy should be repeated at 6 months for incompletely resected polyps or those with high grade dysplasia. Endoscopy can be repeated after 1 year for all other polyps (moderate, trade offs, qualified).

### Hamartomatous polyps

Hamartomatous polyps are rare in the stomach and include juvenile polyps, polyps of Peutz–Jeghers' syndrome (PJS), and Cowden's disease. The follow-up recommendations of patients with these conditions are summarised in table 1.

### Juvenile polyps

Juvenile polyps are found in the antrum. Solitary polyps have hamartomatous or inflammatory components and do not have a neoplastic potential. Histologically, these show irregular cysts lined by normal gastric epithelium; with possible stromal haemorrhage, surface ulceration and chronic inflammation due

**Table 1** Management of gastric polyps associated with polyposis syndromes

Syndrome	Lifetime risk of malignancy	Surveillance recommendation
Familial adenomatous polyposis	100% (colon)	OGD every 2 years after age 18 Biopsy >5 polyps Remove polyps >1 cm Surveillance also required for duodenal polyps
Peutz–Jeghers'	>50% (extra-GI)	OGD every 2 years after age 18 Biopsy >5 polyps Remove polyps >1 cm
Juvenile polyposis	>50%	OGD every 3 years after age 18
Cowden's	Rare	Eradicate <i>H pylori</i> No further OGD needed

There is very little evidence for the following recommendations, but given the high risk of malignancy in these conditions careful surveillance is necessary.  
GI, gastro-intestinal; OGD, gastroscopy.

to torsion. Multiple polyps are associated with juvenile polyposis.

### Peutz–Jeghers' syndrome

PJS is a rare autosomal dominant inherited condition, characterised by the presence of hamartomatous gastrointestinal polyps and mucocutaneous pigmentation of the lips, buccal mucosa and digits. Microscopically, hyperplastic glands lined by foveolar epithelium and broad bands of smooth muscle fibres that branch out are found. PJS increases the risk of both gastrointestinal cancer through the hamartoma–adenoma–carcinoma sequence and de novo malignant change. There is a 15-fold increase in extra-intestinal malignancies such as breast, endometrial, pancreatic and lung cancers.<sup>54</sup>

#### *Recommendation for PJS gastric polyps*

- ▶ Gastric polyps greater than 1 cm should be removed. As there is a high rate of recurrence, regular endoscopic follow-up and annual screening of other susceptible organs is recommended (moderate, trade offs, qualified).

### Cowden's syndrome

Cowden's syndrome (CS) or multiple hamartoma syndrome is a rare autosomal dominant syndrome characterised by orocutaneous hamartomatous tumours, gastrointestinal polyps, abnormalities of the breast, thyroid gland and genitourinary system. The gastrointestinal polyps are generally benign and malignant transformation is seen very rarely. Common benign visceral tumours and hyperplastic conditions include gastrointestinal polyps, thyroid adenoma and goitre and, fibrocystic disease of the breast in female patients, and gynaecomastia in male patients. Malignancies of the thyroid, colon, small bowel, and genitourinary tract have been reported, as well as acute myelogenous (myeloid) leukaemia, non-Hodgkin's lymphoma and breast carcinoma. Histologically, CS polyps have elongated cystically dilated glands with papillary infoldings with a connective tissue (neural or muscular) component.

### Familial polyposis syndromes

A summary of the cancer risk and screening recommendations for the familial polyposis syndromes is shown in table 1.

#### Familial adenomatous polyposis

Familial adenomatous polyposis (FAP) is caused by a germline mutation in the adenomatous polyposis coli APC gene on chromosome 5q21 and has an autosomal dominant inheritance and a high incidence of gastric cancer. Affected family members develop numerous colorectal adenomas with virtually a 100% chance of malignant progression unless the colon is removed prophylactically.

Gastric polyps occur in 30–100% of cases of FAP and these patients are said to have familial gastric polyposis (FGP). Most polyps are benign fundic gland polyps and gastric adenomatous polyps occur in only 5%, usually in the antrum. Duodenal adenomas and periampullary adenomas occur in 50–90% of patients,<sup>55 56</sup> are usually malignant and are the main cause of mortality after prophylactic colectomy. There is a negative association with *H pylori*-associated chronic gastritis.<sup>57</sup> Sampling of polyps is required to determine whether they are adenomas or FGPs. Endoscopic surveillance of small gastric and duodenal polyps is required every 1–2 years until the patient reaches the age of 50 years but large polyps/adenomas may require more frequent surveillance. Surveillance frequency can be reduced to five yearly after the age of 50 years. Partial gastrectomy and local

duodenal resection or pancreaticoduodenectomy may be required in selected patients.

#### Juvenile polyposis

This condition is associated with numerous mutations (BMPR1A, 10q22.3, SMAD4, 18q21.1) and is associated with gastric malignancy in over 50% of cases.<sup>58 59</sup> Juvenile polyposis is also associated with gastrointestinal bleeding<sup>60</sup> and protein-losing enteropathy. Histologically, the glands are tortuous, elongated and cystically dilated and the background mucosa is oedematous and inflamed.

#### Inflammatory fibroid polyps

Inflammatory fibroid polyps (IFPs) constitute 3% of all BEGP<sup>5</sup> and are well-circumscribed lesions located in the antrum or prepyloric region, covered with a smooth surface of normal mucosa. They originate from the submucosa and should not be confused with 'inflammatory polyps', which are a commonly used misnomer for hyperplastic polyps. They occur in patients of all ages, but more commonly in the fifth to sixth decades of life, and more frequently in females. They do not have a malignant potential but are associated with chronic atrophic gastritis. Their aetiology remains obscure but there is a weak association with *H pylori*.<sup>61</sup> Polyps grow to 1–5 cm in diameter and the larger lesions often have a central depression, ulceration or a white cap. IFPs remain unchanged and asymptomatic for a long time but have the propensity to enlarge and cause gastric obstruction.

Histology shows blood vessels surrounded by spindle cells (CD 34 and fascin positive) and chronic inflammatory cells, predominantly eosinophils. Multinucleated giant cells may be present, but they are not associated with a systemic allergic reaction or eosinophilia. IFPs may be amenable to complete endoscopic excision but extension into the deeper layers of the gastric wall sometimes preclude this, and for very deep polyps, forceps biopsy may be negative.

#### Gastric neuroendocrine tumours (carcinoids)

Management of gastric neuroendocrine tumours is discussed in detail in 'Guidelines for the management of gastroenteropancreatic neuroendocrine (including carcinoid) tumours'<sup>62</sup> and will therefore only be summarised here. Most gastric NETs are composed of enterochromaffin-like (ECL) cells, which be identified histopathologically by immunostaining for markers such as chromogranin A or synaptophysin. There are three main subtypes. Type 1 tumours (approximately 80% of total) are usually sessile polyps and associated with (usually autoimmune) atrophic gastritis, pernicious anaemia, achlorhydria and hypergastrinaemia, with the elevated gastrin being produced by gastric antral G cells. Type 2 gastric NETs (approximately 5% of total) occur in patients with Zollinger–Ellison syndrome, usually in the setting of multiple endocrine neoplasia type 1 (MEN1). They are therefore associated with gastrinomas, hypergastrinaemia and gastric hyperacidity. Type 3 gastric NETs (approximately 15%) occur sporadically and are not associated with hypergastrinaemia.<sup>63 64</sup>

Treatment and prognosis is determined by tumour type, size of polyp(s) and by the presence or absence of metastases.<sup>62</sup> Type 1 tumours carry a very good prognosis and may need no treatment if the tumours are small (<1 cm). Larger type 1 NETs should be treated by endoscopic polypectomy or surgical antrectomy should be considered. Type 2 gastric NETs usually regress if the gastrinoma can be completely removed surgically. Type 3 gastric NETs are associated with the worst prognosis and

## Guidelines

should be treated by surgical resection. Metastatic tumours of all types are amenable to a range of palliative treatments, as discussed in more detail elsewhere.<sup>62</sup>

### Recommendations for management of gastric NET

- ▶ The type of gastric NET should be determined in each case by biopsy of the lesion and surrounding normal mucosa, and measuring fasting serum gastrin concentration (moderate, trade offs, qualified).
- ▶ Tumours should be staged appropriately and treatment options should be discussed with a neuroendocrine tumour multidisciplinary team (moderate, benefit, definitive).

### Stromal tumours

Management of gastrointestinal stromal tumours (GISTs) is discussed in detail in the document 'Consensus meeting for the management of gastrointestinal stromal tumors'.<sup>65</sup> Therefore only a brief summary will be included here.

GISTs are rare connective tissue tumours that show similar differentiation patterns to the interstitial cells of Cajal and approximately 60–70% arise in the stomach. Activating mutations of the KIT or PDGFRA protooncogenes are thought to be the causal molecular events. Approximately 95% of tumours are therefore positive for CD117 (c-KIT) by immunohistochemistry. The degree of local and metastatic spread of gastric GISTs should be evaluated by CT scan and endoscopic ultrasound. If the tumour is localised to the stomach it should be surgically resected. If the tumour is unresectable or if metastases are present at diagnosis or during follow-up, treatment with the tyrosine kinase inhibitor, imatinib, should be considered and treatment should usually be continued until progression, intolerance or patient refusal occurs. NICE guidelines on the use of imatinib therapy in this tumour type are available.<sup>66</sup>

## ENDOSCOPIC RECOMMENDATIONS

### Biopsying the gastric mucosa

Given that most polyps found at endoscopy will be FGPs and therefore biopsies of the gastric mucosa are not indicated, it is not cost effective to recommend biopsying the surrounding mucosa in everyone. If biopsies are taken at the index endoscopy they do not need to be repeated at subsequent procedures. However, if they have not been taken, they are needed in patients with hyperplastic and adenomatous polyps.

### Polyp sampling; forceps biopsy or polypectomy

Sampling of polyps greater than 5 mm by forceps biopsy raises concern about whether it is representative of the whole polyp or whether dysplasia or cancer may be missed. A prospective multi-centre study of 222 endoscopically removable polyps (excluding fundic gastric polyps and polyposis syndrome) showed complete histological agreement between initial biopsies and polypectomy in 55.8% of cases and in 34.7% differentiation between tumour-like lesions and neoplasia was possible.<sup>67</sup> However, in 2.7% relevant differences were found, the most common being failure of biopsy to reveal foci of carcinoma in hyperplastic polyps. Thus the correct histological diagnosis can be obtained without a complete polypectomy in 97.3% of cases. Other series which looked at whether forceps biopsy is representative of the whole polyp showed discrepancy with rates ranging from 0% to 29%.<sup>68–71</sup> Occasionally, biopsies reveal normal mucosa in a gastric polypoid lesion, which may indicate either missed sampling or a submucosal, intramural or less commonly an extra-gastric lesion.

There is a higher rate of disagreement for sessile gastric polyps and flat lesions, and in one series assessing flat early gastric

cancers only 55% of biopsies agreed with histology of endoscopic mucosal resections (EMR).<sup>72</sup>

There is limited data on complications following gastric polypectomy for benign polyps. Most studies in this area have evaluated the role of endoscopic therapy for treating early gastric cancers. Snare polypectomy and EMR in the stomach carry a high risk of complications. In the largest study, 7.2% patients had post-polypectomy bleeding, 80% of whom needed endoscopic therapeutic intervention.<sup>67</sup> Endoscopic mucosal resection (EMR) and endoscopic mucosal dissection (EMD) of 479 flat and raised early gastric cancers in Japan had a bleeding and perforation rate of 5%.<sup>73</sup>

Therefore, given the risks of gastric polypectomy, it may be safer to only biopsy polyps in patients with co-morbidity or at risk of haemorrhage. Polyps <1 cm probably only require two biopsies, whereas larger polyps require three to four biopsies. The risks of polypectomy also require the clinician to be confident that polypectomy is indicated. Thus, given the difficulty in confirming definite dysplasia in some polyps, an agreement by two histopathologists that dysplasia is present is ideal before embarking on polypectomy.

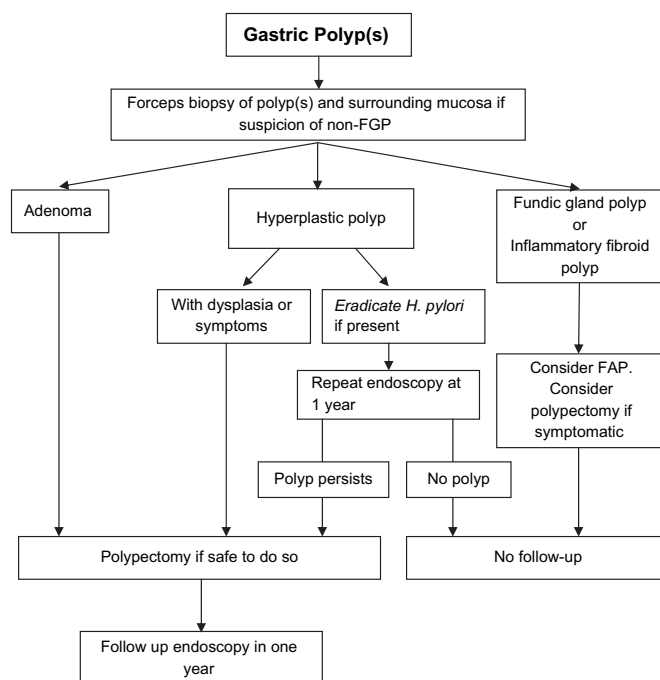
### Recommendations for gastric polypectomy

- ▶ Any polyp with a dysplastic focus should be completely removed when safe to do so (moderate, trade offs, qualified)
- ▶ Endoscopists performing gastric polypectomy should be competent to manage the complications of bleeding (high, benefit, definitive).
- ▶ The decision to perform a polypectomy must be weighed against the risk of complications especially in elderly patients with concomitant illness (high, benefit, definitive).

An algorithm for the management of single and multiple gastric polyps is given in figure 1.

### Endoscopic follow-up

All gastric polyps except FGPs and inflammatory fibroid polyps are associated with significantly increased gastric cancer risk. Table 2 summarises the characteristics of gastric polyps and their cancer risk.



**Figure 1** Algorithm for the management of gastric polyps. FAP, familial adenomatous polyposis.

**Table 2** Gastric polyp characteristics and malignant potential

Polyp type	Usual number and size	Usual site	Malignant potential of polyp	Malignant potential of background mucosa	Management
Sporadic fundic gland polyp	Multiple 1–5 mm	Upper and lower body	Very low	Very low	Biopsy to confirm nature of polyp No follow-up needed
Familial adenomatous polyposis-associated fundic gland polyp	Multiple 'carpet' <1 cm	Upper and lower body	Low	Low	Biopsy to confirm nature of polyp Repeat OGD every 2 years
Hyperplastic	Single 1–2 cm	Antrum	Low but significant	Low	Remove polyp if dysplastic Eradicate <i>H pylori</i> Repeat OGD 1 year
	Multiple <1 cm	Lower body	Low but significant	Low	Eradicate <i>H pylori</i> Repeat OGD 1 year
Adenoma	Single 1–2 cm	Antrum	High	Significant	Remove polyp Sample rest of gastric mucosa Repeat OGD at 1 year
Inflammatory fibroid polyp	Single 1–5 cm	Antrum	Very low	Very low	Biopsy to confirm nature of polyp Remove if causing obstruction No follow-up

OGD, gastroscopy.

There is no evidence as to whether gastric polyps need long-term surveillance, and given the cost implications of such a programme, only a single gastroscopy 1 year after the removal of polyps with dysplasia is recommended (in the absence of polyp syndromes).

## FUTURE RESEARCH AND AUDIT

### Future research topics

The following are areas that preparation of these guidelines revealed as needing further research:

- ▶ The necessity of biopsying 'typical appearing' FGPs
- ▶ The prevalence of FAP in young patients with >20 FGPs
- ▶ The natural history of gastric polyps with and without dysplasia
- ▶ The efficacy of *H pylori* eradication in patients with hyperplastic polyps
- ▶ The risks/benefits of different surveillance intervals for gastroscopy following polypectomy
- ▶ The risks/benefits of polypectomy versus biopsy for non-adenomatous gastric polyps

### Audit targets

We recommend the following targets for audit:

- ▶ >95% of single gastric polyps should be sampled together with the surrounding mucosa where necessary
- ▶ >80% of adenomatous polyps should be removed and retrieved
- ▶ >90% of patients with gastric polyps in whom *H pylori* is detected should have it eradicated successfully

## CONCLUSIONS

The management of a patient in whom a gastric polyp has been detected endoscopically must include typing the lesion by histology and assessment of dysplasia. Most gastric polyps are benign and need minimal intervention or follow-up. However, some types of gastric polyp have significant malignant potential and it is the responsibility of the endoscopist to ensure that such polyps are identified and managed appropriately.

**Competing interests** None declared.

**Provenance and peer review** Not commissioned; externally peer reviewed.

## REFERENCES

1. **Atkins D**, Best D, Briss PA, *et al*. Grading quality of evidence and strength of recommendations. *Br Med J* 2004;**328**:1490.
2. **Deppisch L**, Rona VT. Gastric epithelial polyps. A 10 year study. *J Clin Gastroenterol* 1989;**11**:110–15.
3. **Jass JR**, Sobin LH, Watanabe H. The World Health Organization's histologic classification of gastrointestinal tumours. A commentary on the second edition. *Cancer* 1990;**66**:2162–7.
4. **WHO classification of Tumours. Pathology and genetics: tumours of the digestive system**. Lyon, France: IARC Press, 2000.
5. **Stolte M**, Stich T, Eidt S, *et al*. Frequency, location and age and sex distribution of various types of gastric polyps. *Endoscopy* 1994;**26**:659–65.
6. **Morais DJ**, Yamanaka A, Zeitun JM, *et al*. Gastric polyps: a retrospective analysis of 26,000 digestive endoscopies. *Arq Gastroenterol* 2007;**44**:14–17.
7. **Borch K**, Skarsgard J, Franzen L, *et al*. Benign gastric polyps: morphological and functional origin. *Dig Dis Sci* 2003;**48**:1293.
8. **Weston BR**, Helper DJ, Rex DK. Positive predictive value of endoscopic features deemed typical of gastric fundic gland polyps. *J Clin Gastroenterol* 2003;**36**:399–402.
9. **Abraham SC**, Nobukawa B, Giardiello FM, *et al*. Fundic gland polyps in familial adenomatous polyposis coli gene alteration. *Am J Pathol* 2000;**157**:747–54.
10. **Jalving M**, Koornstra JJ, Wesseling J, *et al*. Increased risk of fundic gland polyps during long-term proton pump inhibitor therapy. *Aliment Pharmacol Ther* 2006;**24**:1341–8.
11. **Abraham SC**, Nobukawa B, Giardiello FM, *et al*. Sporadic fundal gland polyps: common gastric polyps arising through activating mutations in the beta-catenin gene. *Am J Pathol* 2001;**158**:1005–10.
12. **Sekine S**, Shibata T, Yamauchi Y, *et al*. Beat-catenin mutations in sporadic fundal gland polyps. *Virchows Arch* 2002;**440**:381–6.
13. **Burt R**. Clinical management: gastric fundal gland polyps. *Gastroenterology* 2003;**125**:1462–9.
14. **Wu TT**, Kornacki S, Rashid A, *et al*. Dysplasia and dysregulation of proliferation in foveolar and surface epithelia of fundic gland polyps from patients with familial adenomatous polyposis. *Am J Surg Pathol* 1998;**22**:293–8.
15. **Jalving M**, Koornstra JJ, Gotz JM, *et al*. High-grade dysplasia in sporadic fundic gland polyps: a case report and review of the literature. *Eur J Gastroenterol Hepatol* 2003;**15**:1153–6.
16. **Stolte M**, Vieth M, Ebert MP. High-grade dysplasia in sporadic fundic gland polyps: clinically relevant or not. *Eur J Gastroenterol Hepatol* 2003;**15**:1229–33.
17. **Stolte M**. Clinical consequences of the endoscopic diagnosis of gastric polyps. *Endoscopy* 1995;**27**:32–7.
18. **Dickey W**, Kenny BD, McConnell JB. Prevalence of fundic gland polyps in a western European population. *J Clin Gastroenterol* 1996;**23**:73–5.
19. **Sakai N**, Tatsula M, Hirasawa R, *et al*. Low prevalence of Helicobacter pylori infection in patients with hamartomatous fundic polyps. *Dig Dis Sci* 1998;**43**:766–72.
20. **Shand AG**, Taylor AC, Banerjee M, *et al*. Gastric fundic gland polyps in south-east Scotland: absence of adenomatous polyposis coli gene mutations and a strikingly low prevalence of Helicobacter pylori infection. *J Gastroenterol Hepatol* 2002;**17**:1161–4.
21. **Watanabe N**, Seno H, Nakajima T, *et al*. Regression of fundic gland polyps following acquisition of Helicobacter pylori. *Gut* 2004;**53**:1721.
22. **El-Zimaity HMT**, Jackson FW, Graham DY. Fundic gland polyps developing during omeprazole therapy. *Am J Gastroenterol* 1997;**92**:1858–60.

23. **Choudhry U**, Boyce HW Jr, Coppola D. Proton pump inhibitor-associated gastric polyps: A retrospective analysis of their frequency, and endoscopic, histologic, and ultrastructural characteristics. *Am J Clin Pathol* 1998;**110**:615–21.
24. **Declich P**, Ferrara A, Galati F, *et al*. Do fundic gland polyps develop under long term omeprazole therapy? *Am J Gastroenterol* 1998;**93**:1393.
25. **Declich P**, Ambrosiani A, Bellone S, *et al*. Fundic gland polyps under omeprazole treatment. *Am J Clin Pathol* 1999;**112**:576–8.
26. **Vieth M**, Stolte M. Fundic gland polyps are not induced by proton pump inhibitor therapy. *Am J Clin Pathol* 2001;**116**:716–20.
27. **Klinkenberg-Knol E**, Nelis F, Dent J, *et al*. Long term omeprazole treatment in resistant gastroesophageal reflux disease: Efficacy, safety and influence on gastric mucosa. *Gastroenterology* 2000;**118**:661–9.
28. **Bianchi LK**, Burke CA, Bennett AE, *et al*. Fundic gland dysplasia is common in familial adenomatous polyposis. *Clin Gastroenterol Hepatol* 2008;**6**:180–5.
29. **Abraham SC**, Nobukawa B, Giardiello FM, *et al*. Fundic gland polyps in familial adenomatous polyposis: neoplasms with frequent somatic adenomatous polyposis coli gene alterations. *Am J Pathol* 2000;**157**:747–54.
30. **Declich P**, Tavani E, Ferrara A, *et al*. Sporadic fundic gland polyps: clinicopathological features and associated diseases. *Pol J Pathol* 2005;**56**:131–7.
31. **Jung A**, Vieth M, Maier O, *et al*. Fundic gland polyps (Elster's cysts) of the gastric mucosa. A marker for colorectal epithelial neoplasia? *Pathol Res Pract* 2002;**198**:731–4.
32. **Abraham SC**, Singh VK, Yardley JH, *et al*. Hyperplastic polyps of the stomach: association with histological patterns of gastritis and gastric atrophy. *Am J Surg Pathol* 2001;**25**:500.
33. **Ohkusa T**, Miwa H, Kumagai J, *et al*. Endoscopic, histological and serologic findings of gastric hyperplastic polyps after eradication of *Helicobacter pylori*: comparison between responder and non-responder cases. *Digestion* 2003;**68**:57–62.
34. **Ohkusa T**, Takashimizu I, Fujiki K, *et al*. Disappearance of hyperplastic polyps in the stomach after eradication of *Helicobacter pylori*. A randomised, clinical trial. *Ann Intern Med* 1998;**129**:712–15.
35. **Ji F**, Wang ZW, Ning JW, *et al*. Effect of drug treatment on hyperplastic polyps infected with *Helicobacter pylori*: a randomized, controlled trial. *World J Gastroenterol* 2006;**12**:1770–3.
36. **Ljubicić N**, Banić M, Kujundžić M, *et al*. The effect of eradicating *Helicobacter pylori* infection on the course of adenomatous and hyperplastic gastric polyps. *Eur J Gastroenterol Hepatol* 1999;**11**:727–30.
37. **Ginsberg GG**, Al-Kawas FH, Fleischer DE, *et al*. Gastric polyps; relationship of size and histology to cancer risk. *Am J Gastroenterol* 1996;**91**:714–17.
38. **Daibo M**, Itabashi M, Hirota T. Malignant transformation of gastric hyperplastic polyps. *Am J Gastroenterol* 1987;**82**:1016–25.
39. **Rattan J**, Arber N, Tiomy E, *et al*. Gastric polypoid lesions: an eight year study. *Hepatogastroenterol* 1993;**40**:107–9.
40. **Dirschmid K**, Platz-Baudin C, Stolte M. Why is the hyperplastic polyp a marker for precancerous condition of the gastric mucosa. *Virchows Arch* 2006;**448**:80–4.
41. **Orlowska J**, Pietrow D. Multifocal gastric carcinoma arising hyperplastic and adenomatous polyps. *Am J Gastroenterol* 1990;**85**:1629–34.
42. **Hizawa K**, Fuchigami T, Iida M, *et al*. Possible neoplastic transformation within gastric hyperplastic polyp. Application of endoscopic polypectomy. *Surg Endosc* 1995;**9**:714–18.
43. **Zea Iriarte WL**, Sekine I, Itsuno M, *et al*. Carcinomas in gastric hyperplastic polyps. A phenotypic study. *Dig Dis Sci* 1996;**41**:377–86.
44. **Orlowska J**, Jarosz D, Pachlewski J, *et al*. Malignant transformation of benign epithelial polyps. *Am J Gastroenterol* 1995;**90**:2152–9.
45. **Cristallini E**, Ascani S, Bolis G. Association between histologic type of polyp and carcinoma in the stomach. *Gastrointest Endosc* 1992;**38**:481–4.
46. **Harju E**. Gastric polyposis and malignancy. *Br J Surg* 1986;**73**:532–3.
47. **Al-Haddad M**, Ward EM, Bouras EP, *et al*. Hyperplastic polyps of the gastric antrum in patients with gastrointestinal blood loss. *Dig Dis Sci* 2007;**52**:105–9.
48. **Yoshihara M**, Sumii K, Haruma K, *et al*. Correlation of ratio of serum pepsinogen I and II with prevalence of gastric cancer and adenoma in Japanese subjects. *Am J Gastroenterol* 1998;**93**:1090–6.
49. **Saito K**, Arai K, Mori M, *et al*. Effect of *Helicobacter pylori* eradication on malignant transformation of gastric adenoma. *Gastrointest Endosc* 2000;**52**:27–32.
50. **Tomasulo J**. Gastric polyps. Histologic types and their relationship to gastric carcinoma. *Cancer* 1971;**27**:1346–55.
51. **Nakamura T**, Nakano G. Histological classification and malignant change in gastric polyps. *J Clin Pathol* 1985;**38**:754–64.
52. **Schmitz JM**, Stolte M. Gastric polyps as precancerous lesions. *Gastrointest Endosc Clin N Am* 1997;**7**:29–46.
53. **Lanza FL**, Graham DY, Nelson, *et al*. Endoscopic upper gastrointestinal polypectomy. Report of 73 polypectomies in 63 patients. *Am J Gastroenterol* 1981;**75**:345–8.
54. **Giardiello FM**, Welsh SB, Hamilton SR. Increased risk of cancer in the Peutz-Jeghers syndrome. *N Engl J Med* 1987;**316**:1511–14.
55. **Debrinsky HS**, Spigelman AD, Hatfield A, *et al*. Upper intestinal surveillance in familial adenomatous polyposis. *Eur J Cancer* 1995;**31**:1149.
56. **Burt RW**. Hereditary polyposis syndromes and inheritance of adenomatous polyps. *Semin Gastrointest Dis* 1992;**3**:13.
57. **Nakamura S**, Matsumoto T, Kobori Y, *et al*. Impact of *Helicobacter pylori* infection and mucosal atrophy on gastric lesions in patients with familial adenomatous polyposis. *Gut* 2002;**51**:485–9.
58. **Howe JR**, Mitros FA, Summers RW. The risk of gastrointestinal carcinoma in familial juvenile polyposis. *Ann Surg Oncol* 1998;**5**:751–6.
59. **Hizawa K**, Iida M, Yao T, *et al*. Juvenile polyposis of the stomach: clinicopathological features and its malignant potential. *J Clin Pathol* 1997;**50**:771–4.
60. **Winkler A**, Hinterleitner TA, Hogenauer C, *et al*. Juvenile polyposis of the stomach causing recurrent upper gastrointestinal bleeding. *Eur J Gastroenterol Hepatol* 2007;**19**:87–90.
61. **Hirasaki S**, Matsubara M, Ikeda F, *et al*. Gastric inflammatory fibroid polyp treated with *Helicobacter pylori* eradication therapy. *Intern Med* 2007;**46**:855–8.
62. **Ramage JK**, Davies AHG, Ardill J, *et al*; on behalf of UKNetwork for neuroendocrine tumours. Guidelines for the management of gastroenteropancreatic neuroendocrine (including carcinoid) tumours. *Gut* 2005;**54**(Suppl 4):iv1–16.
63. **Burkitt MD**, Pritchard DM. Review article: pathogenesis and management of gastric carcinoid tumours. *Aliment Pharmacol Ther* 2006;**24**:1305–20.
64. **Modlin IM**, Lye KD, Kidd M. Carcinoid tumors of the stomach. *Surg Oncol* 2003;**12**:153–72.
65. **Anon**. Consensus meeting for the management of gastrointestinal stromal tumors: report of the GIST Consensus Conference of 20–21 March 2004. *Ann Oncol* 2005;**16**:566–78.
66. **National Institute for Clinical Excellence**. *NICE Technology Appraisal Guidance 86. Imatinib for the treatment of unresectable and/or metastatic gastro-intestinal stromal tumours*. London: National Institute for Clinical Excellence, 2004.
67. **Mueldorfer SM**, Stolte M, Martus P, *et al*. Diagnostic accuracy of forceps biopsy versus polypectomy for gastric polyps: a prospective multicentre study. *Gut* 2002;**50**:465–70.
68. **American Society of Gastrointestinal Endoscopy**. The role of endoscopy in the surveillance of premalignant condition of the upper gastrointestinal tract. *Gastrointest Endosc* 1998;**48**:663–8.
69. **Seifert E**, Elster K. Gastric polypectomy. *Am J Gastroenterol* 1975;**63**:451–6.
70. **Ottenjann R**, Kunert H, Seib HJ. Is gastroscopic polypectomy a diagnostic necessity? Results of a prospective study. *Dtsch Med Wochenschr* 1984;**109**:443–5.
71. **Chua CL**. Gastric polyps: the case for polypectomy and endoscopic surveillance. *J R Coll Surg Edinb* 1990;**35**:163–5.
72. **Szaloki T**, Toth V, Tiszlavicz L, *et al*. Flat gastric polyps: results of forceps biopsy, endoscopic mucosal resection, and long-term follow-up. *Scand J Gastroenterol* 2006;**41**:1105–8.
73. **Ono H**, Kondo H, Gotoda T, *et al*. Endoscopic mucosal resection for treatment of early gastric cancer. *Gut* 2001;**48**:225–9.

#### APPENDIX 1 Members of the Gastric Polyp Guideline Consensus Panel Meeting, held 22 November 2009, St Mary's Hospital, London

Dr Yeng Ang  
 Professor Emad El-Omar  
 Dr Andrew F Goddard (co-chair)  
 Dr Robert Goldin  
 Dr Philip Hardo  
 Dr Robert PH Logan  
 Professor Kenneth McColl  
 Professor D Mark Pritchard  
 Dr Tony Tham  
 Dr Marjorie M Walker (co-chair)